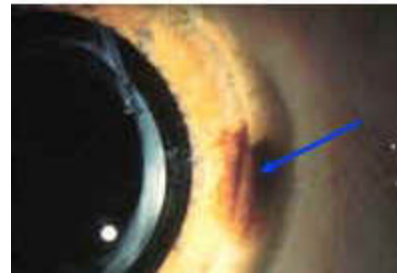
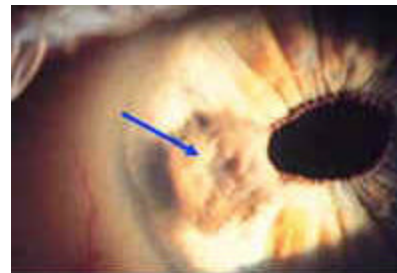
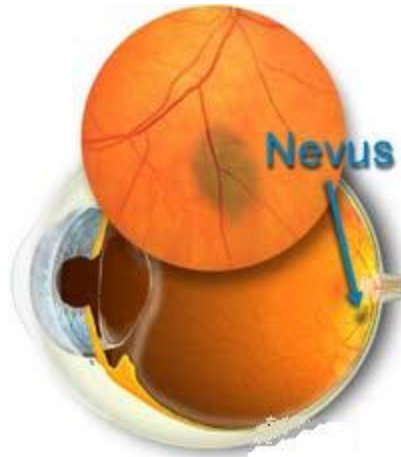


Nevus

Overview

A nevus is typically a flat, benign, pigmented area that may appear inside the eye or on its surface. Nevi commonly appear on the choroid (the layer just behind the **retina**), the **iris**, and the **conjunctiva**. Nevi are similar to freckles, and don't typically change or grow.



Signs and Symptoms

- Brownish, freckle-like spot
- Usually flat

Detection and Diagnosis

Nevi of the conjunctiva or iris can be detected with a **slit lamp microscope**. If the nevus occurs within the eye, it is evaluated with an **ophthalmoscope**.

Treatment

Nevi are usually harmless, but it's always wise to monitor them for changes. This can be done with photos and sometimes ultrasound. The doctor will document the size, shape and whether the nevus is elevated. In rare cases, the nevus must be biopsied and examined for melanoma (cancer) cells.